

Case Report

Peduncular Hallucinosis and Overlapping Antiganglioside Antibody Syndrome

Alexis Demas^{1,*}, Guillaume Costentin², Vincent Langlois³, Yvan Vaschalde¹,
Jean Philippe Cochin¹

¹Department of Neurology, Hospital Jacques Monod, Le Havre, France

²Department of Neurology, University Hospital Charles Nicolle, Rouen, France

³Department of Internal Medicine and Infectious Diseases, Hospital Jacques Monod, Le Havre, France

Email address:

alexis.demas@ch-lehavre.fr (A. Demas), guillaume-costentin@hotmail.fr (G. Costentin), vincent.langlois@ch-havre.fr (V. Langlois),
yvan.vaschalde@ch-havre.fr (Y. Vaschalde), jeanphilippe.cochin@ch-havre.fr (J. P. Cochin)

*Corresponding author

To cite this article:

Alexis Demas, Guillaume Costentin, Vincent Langlois, Yvan Vaschalde, Jean Philippe Cochin. Peduncular Hallucinosis and Overlapping Antiganglioside Antibody Syndrome. *American Journal of Psychiatry and Neuroscience*. Vol. 7, No. 1, 2019, pp. 8-11.

doi: 10.11648/j.ajpn.20190701.12

Received: November 15, 2018; **Accepted:** December 17, 2018; **Published:** May 27, 2018

Abstract: Guillain Barre Syndrome (GBS), Miller Fisher Syndrome (MFS) and Bickerstaff Brainstem Encephalitis (BBE) form part of the same disease spectrum, sharing some clinical signs and auto-immune based mechanisms with antiganglioside antibodies. GBS, the most common cause of subacute flaccid paralysis, is a well-known and extensively described syndrome. MFS is characterized by subacute ophthalmoplegia, ataxia and areflexia. In 1957, Bickerstaff described some patients who, in addition to ataxia and ophthalmoplegia, had abnormal mental status, corresponding to brainstem involvement. Neurological manifestations associated with anti-GQ1b antibodies can occur in isolation or in association. We report the case of a woman with an unusual psychiatric presentation (peduncular hallucinosis) of anti-GQ1b antibody syndrome, with features of these three diseases, and a dramatic improvement with immunoglobulin therapy. Peduncular hallucinosis are a rare form of visual hallucination. They are often described as colourful visions of people and animals, and are usually associated with vascular lesions in the midbrain and thalamus. This provides further evidence of the broad spectrum of neurological diseases associated with antiganglioside antibodies. To the best of our knowledge this is the first description of PH complicating BBE. Clinicians should be aware of the existence of overlapping syndrome with combined central and peripheral neurological system involvement.

Keywords: Antiganglioside Antibodies Overlapping Syndromes, Guillain Barre, Miller Fisher, Bickerstaff's Brainstem Encephalitis, Peduncular Hallucinosis

1. Introduction

Guillain-Barré Syndrome (GBS) [1], Miller Fisher Syndrome (MFS) [2] and Bickerstaff brainstem encephalitis (BBE) [3] form part of the same disease spectrum, sharing some clinical signs and auto-immune based mechanisms with antiganglioside antibodies [4]. GBS, the most common cause of subacute flaccid paralysis, is a well-known and extensively described syndrome. MFS is characterized by subacute ophthalmoplegia, ataxia and areflexia. In 1957, Bickerstaff

described some patients who, in addition to ataxia and ophthalmoplegia, had abnormal mental status, corresponding to brainstem affection. Clinicians should be aware of the existence of overlapping syndrome with combined central and peripheral nervous system involvement.

2. Method

We report the case of a woman with features of these three diseases. She experienced an unusual initial psychiatric

presentation (peduncular hallucinosis), providing further evidence of the difficulties to diagnose overlapping antiganglioside antibody syndromes.

A 72-year-old woman was addressed for agitation. Fever (40°C) was noted four days before consultation. A rapidly diffuse motor weakness and abnormal mental status were observed until this episode. Upon admission, she was confused. Her husband reported complex and bizarre visual hallucinations (vivid children playing in the bathroom) the day before. On examination, drowsiness, tetraparesis (bilateral and symmetrical weak contraction against gravity (3/5) of upper and lower extremities of arms and legs, neck flexors), ataxia,

areflexia, bilateral areactive mydriasis with external ophthalmoplegia and slurred speech were noted. Plantar flexor responses were absent. Distal paresthesias were described, without hypoesthesia. A routine blood test was normal. Magnetic resonance imaging revealed isolated chronic vascular leukoencephalopathy. Cerebro-spinal fluid analysis performed four days after the beginning of the symptoms, was normal. A second CSF analysis on the sixth day showed lymphocytic meningitis (36 cells per mm³, 100% lymphocytes), without hyperproteinorachia. The electroencephalogram was slow, with diffuse delta and theta waves (figure 1).

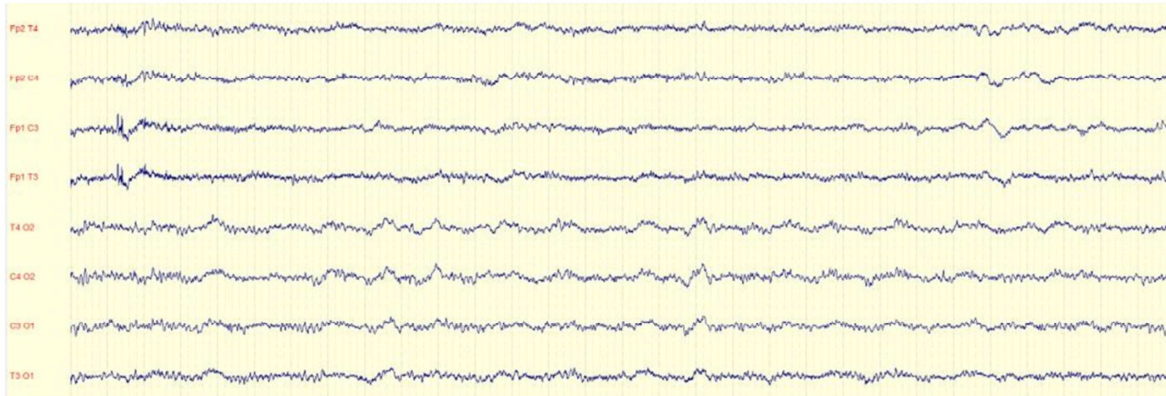


Figure 1. Initial electroencephalogram. Cerebral activity was slow, with diffuse delta and theta waves.

Serological tests (HIV, Haemophilus influenza, Campylobacter jejuni, HBV, HCV) were negative. A Mycoplasma pneumoniae test was positive for IgG. Nerve conduction studies (NCS) showed sensory axonal neuropathy with low-amplitude sensitive potentials. IgM and IgG anti-ganglioside antibodies (anti-GM1, anti-GM2, anti-GM3, anti-GD1a, anti-GD1b, anti-GT1b, anti-GQ1b) in serum were tested (ELISA method). Anti-GQ1b IgG in serum was positive. We started immunoglobulin therapy (35 grams per day for 5 days).

3. Result

During the first day, rapid recovery was noted: mental status and motor signs on the first day, ophthalmoplegia on the second day then proprioceptive ataxia. By the fifth day of therapy, the patient could move to her chair. The electroencephalogram realised on the sixth day was improved (figure 2), with the reappearance of an organized and reactive cerebral activity and the disappearance of slow waves.

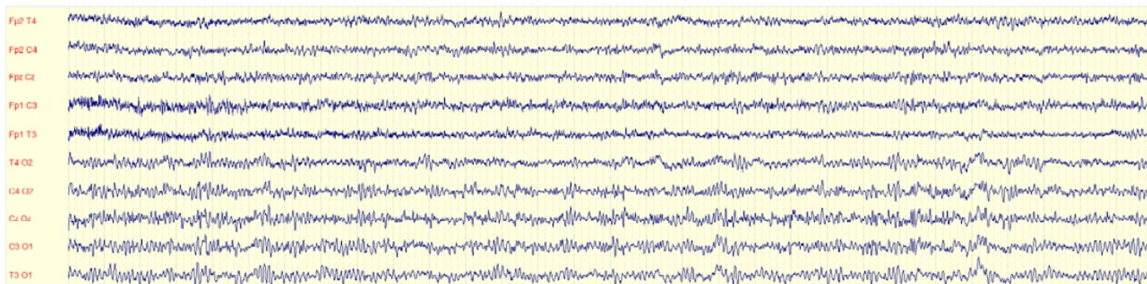


Figure 2. Control of the electroencephalogram. An improvement was noted, with the reappearance of an organized and reactive cerebral activity and the disappearance of slow waves.

One year later, the patient is asymptomatic. MRI, NCS and cognitive assessment are normal. Serum antiganglioside antibody titres are negative.

4. Discussion

This observation indicates that diagnosis in antiganglioside

overlapping syndromes is challenging. Sekiguchi et al. reported that 50% of MFS developed an overlap syndrome with GBS or BBE within 7 days of MFS onset [5]. In BBE, mental symptoms and sleep disturbances are common [6]. However, the initial psychiatric presentation with complex visual hallucinations and agitation is extremely rare [7]. These hallucinations correspond to peduncular hallucinosis (PH), a

rare form of visual hallucination. They are often described as colourful visions of people and animals. PH is usually associated with vascular lesions in the midbrain and thalamus [8; 9]. The exact pathophysiology of PH is unknown. Two mechanisms have been proposed. On the one hand, an imbalance between neurotransmitters in the reticular activating system [10]. In the other a disruption of a closed loop between the basal ganglia and the inferotemporal lobe [11].

In this case, the clinical spectrum was progressively formed over five days of BBE symptoms (motor symptoms and alteration of mental status with peduncular hallucinosis on days one and two), followed by MFS on day three (oculo-motor disorder), then sensory GBS (paresthesia) on day five. The association of visual hallucinations with sleep disturbance, abnormal electroencephalogram and the absence of recurrence of hallucinations without neuroleptic drugs, are strong elements in favour of peduncular hallucinosis occurring in BBE, mediated by antiganglioside antibody.

To make diagnosis even more difficult, MRI is most often normal in BBE [12]. MRI lesions correspond to high-signals on T2-weighted images of the upper mesencephalon, cerebellum, thalamus or brainstem, which may regress over the clinical course of the illness [13]. As an added diagnostic difficulty, atypical lumbar puncture results may occur. Raised proteins in CSF is the main described element, but isolated pleiocytosis can be found. Lumbar puncture may be repeated.

Clinical signs can be explained by target-specific antibodies [14]. GQ1b antigen is strongly expressed at the surface of oculomotor nerves, large-diameter dorsal root ganglion neurons and muscle spindle cells. Antibodies binding to these sites could explain the ophthalmoplegia and ataxia. Confusion, abnormal circadian rhythms and drowsiness, behavioural disturbance and hallucinations in BBE could be explained by the presence of GQ1b complex in the reticular formation.

Involvement of both the peripheral and central nervous system suggests overlapping syndrome associated with anti-ganglioside antibodies, notably mediated by anti-GQ1b antibody. In this case, we retain an anti-GQ1b antibody-positive overlap syndrome. Some similar cases of overlap syndrome, however, have been described without positive anti-GQ1b [15], suggestive of a pathogenesis not exclusively limited to anti-ganglioside antibodies.

Treatment decisions for antiganglioside syndromes remain unclear.

5. Conclusion

This case is remarkable. Initial psychiatric signs, rapidly progressive combined both peripheral and central symptoms, normal MRI and normal early CSF analysis, emphasize the broad range of clinical pictures, along with the difficulties to diagnose overlapping antiganglioside antibody syndromes. To our knowledge, this is the first description of peduncular hallucinosis in a patient with anti-GQ1b syndrome.

Author Contributions

Alexis Demas, drafting the manuscript, study concept or design, analysis or interpretation of data, acquisition of data

Guillaume Costentin, drafting the manuscript, acquisition of data

Vincent Langlois, critical revision of manuscript

Yvan Vaschalde, analysis or interpretation of data, critical revision of manuscript

Jean Philippe Cochin, study concept, critical revision of manuscript

Patient Consent and Declaration of Interest

The patient's written informed consent was obtained.

All co-authors have read and approved the submission.

Authors report no disclosures.

References

- [1] Goodfellow JA, Willison HJ. Guillain-Barré syndrome: a century of progress. *Nat Rev Neurol.* 2016 Dec; 12 (12): 723-731.
- [2] Bukhari S, Taboada J. A Case of Miller Fisher Syndrome and Literature Review. *Cureus.* 2017 Feb 22; 9 (2): e1048.
- [3] Kuwabara S, Misawa S, Mori M. Bickerstaff brainstem encephalitis: more common than we think? *J Neurol Neurosurg Psychiatry.* 2013 Nov; 84 (11): 1184.
- [4] Wakerley BR, Uncini A, Yuki N; GBS Classification Group.; GBS Classification Group. Guillain-Barré and Miller Fisher syndromes - new diagnostic classification. *Nat Rev Neurol.* 2014; 10 (9): 537-44.
- [5] Sekiguchi Y, Mori M, Misawa S, Sawai S, Yuki N, Beppu M, Kuwabara S. How often and when Fisher syndrome is overlapped by Guillain-Barré syndrome or Bickerstaff brainstem encephalitis? *Eur J Neurol.* 2016; (6): 1058-63.
- [6] Abrams JK, Johnson PL, Hollis JH, Lowry CA. Anatomic and functional topography of the dorsal raphe nucleus. *Ann N Y Acad Sci.* 2004; 1018: 46-57.
- [7] Alam A, Puri NV. Inefficacy of Antipsychotics in Treatment of Delirium and Agitation in Two Cases of Bickerstaff Brainstem Encephalitis. *J Neuropsychiatry Clin Neurosci.* 2014 1; 26 (2): 176-8.
- [8] Kölmel HW. Peduncular hallucinosis. *J Neurol.* 1991 Dec; 238 (8): 457-459.
- [9] Couse M, Wojtanoowicz T, Comeau S, Bota R. Peduncular hallucinosis associated with a pontine cavernoma. *Ment Illn.* 2018 May 16; 10 (1): 7586.
- [10] Manfred M, Andermann F. Complex visual hallucinations. Clinical and neurobiological insights. *Brain.* 1998; 121 (Pt 10): 1819-1840.
- [11] Middleton FA, Strick PL. The temporal lobe is a target of output from the basal ganglia. *Proc Natl Acad Sci USA.* 1996; 93 (16): 8683-8687.

- [12] Masaaki Odaka, Nobuhiro Yuki, Mitsunori Yamada, Michiaki Koga, Toshihiko Takemi, Koichi Hirata, Satoshi Kuwabara, Bickerstaff's brainstem encephalitis: clinical features of 62 cases and a subgroup associated with Guillain-Barré syndrome. *Brain*. 2003; 126 (10): 2279-2290.
- [13] Mondéjar RR, Santos JM, Villalba EF. MRI findings in a remitting-relapsing case of Bickerstaff encephalitis. *Neuroradiology*. 2002 May; 44 (5): 411-4.
- [14] Fukami Y, Wong AHY, Funakoshi K, Safri A y., Shahrizaila N, Yuki N. Anti-GQ1b antibody syndrome: anti-ganglioside complex reactivity determines clinical spectrum. *Eur J Neurol*. 2016 Feb 1; 23 (2): 320.
- [15] Stevenson V *et al.* Bickerstaff's brainstem encephalitis, Miller Fisher syndrome and Guillain-Barre syndrome overlap with negative anti-GQ1b antibodies. *Eur J Neurol*. 2003 March 10 (2): 187.