

Prevalence of Radiological Abnormalities Among Psychiatric Inpatients: A Study from the United Arab Emirates

Amir Mufaddel^{1,*}, Ghanem Al Hassani², Shakhboot Al Bedwawi², Ossama Osman³

¹Department of Medicine, Psychiatry Ivision, Tawam Hospital, Al Ain, Nited Arab Emirates

²Al Ain Hospital, Al Ain, Nited Arab Emirates

³Department of Psychiatry and Behavioural Sciences, College of Medicine and Health Sciences, United Arab Emirates University, Alain, United Arab Emirates

Email address:

khalifaamir@yahoo.co.uk (A. Mufaddel)

*Corresponding author

To cite this article:

Amir Mufaddel, Ghanem Al Hassani, Shakhboot Al Bedwawi, Ossama Osman. Prevalence of Radiological Abnormalities Among Psychiatric Inpatients: A Study from the United Arab Emirates. *American Journal of Psychiatry and Neuroscience*. Vol. 7, No. 4, 2019, pp. 147-152. doi: 10.11648/j.ajpn.20190704.19

Received: December 5, 2019; **Accepted:** December 18, 2019; **Published:** December 30, 2019

Abstract: *Background:* This is a cross sectional retrospective study aimed to estimate the prevalence of brain aberrations visible on computed tomography (CT) scan or magnetic resonance imaging (MRI) in psychiatric patients admitted to the main tertiary hospital of Alain city in the United Arab Emirates. *Methods:* Between January 2011 and December 2013, 1,586 patients were admitted study of patients admitted to the psychiatric ward in Al Ain Hospital. Head CT or brain MRI was requested for 295 (19%) patients. *Results:* Ninety-four (31.8%) of the 295 patients had abnormalities on the CT or MRI. The most common finding was calcification, detected in 21 (22.3%) patients. The most common site of calcification was the basal ganglia (15 patients, or 16%). Multiple site involvements were also common (16 patients, or 17%). Other types of brain abnormalities included evolutionary changes (dilated ventricles, atrophy and prominent sulci) reported in 13 patients which represent 4.4% of the total sample and 13.8% of those with positive findings. Similar number was reported for patients with findings of vascular lesions (ischemic changes / infarction). Basal ganglia was the most common site of reported involvement occurring in 19 subjects and representing 6.4% of the total sample and 20.2% of those with positive findings. Common age at presentation with positive findings was 30-39y. *Conclusions:* Radiological abnormalities are common among psychiatric inpatients. Future studies are needed to identify the potential significance of these findings and correlate them with patient's psychopathology.

Keywords: Radiologic Findings, Psychiatric Patients, Brain Sites, Calcifications

1. Introduction

Understanding Radiological findings among psychiatric patients are important for more accurate assessment and management of different aspects of psychiatric presentations.

The literature on CT studies in schizophrenia revealed structural changes including enlargement of the ventricles, cerebral sulci and fissure. Similarly, MRI studies had revealed significant differences in ventricular volume and medial temporal structures among these patients [1].

Radiological investigations are used in the workup of patients with psychiatric symptoms in order to rule out possible underlying neurological conditions. Example of lesions that can be detected by neuroimaging are frontal or temporal lobes tumors [2].

Neuroimaging can be also helpful in differentiating presence of a neurodegenerative condition from depression in older people who present with history of cognitive impairment. Example of these are findings on neuroimaging that can be characteristic of Alzheimer's disease, diffuse Lewy body dementia, or frontotemporal dementias. In

Alzheimer's disease, medial temporal atrophy can be detected by MRI or CT studies [3].

Some studies on the use of brain imaging in first episode psychosis suggest that routine CT or MRI scans are of little benefit and should be reserved for age groups 50 years and older or those with possible neurological problems [4]. Other studies reported about 30% abnormal findings of previously undiagnosed pathology on MRI scans of psychiatric patients [5]. Moreover, several brain imaging studies have shown structural, functional and neurochemical deviations in subjects who were in phase of At Risk Mental State (ARMS) defined as 5 years prodromal period before the manifestations were clear; with findings similar to those observed when the psychosis is clearly established [6]. The MRI findings in individuals who were at high risk of schizophrenia have shown a significantly higher proportion of radiological findings in individuals who were at high risk of schizophrenia (35%) as well as those who developed first - episode psychosis (40%) compared with patients with depression (18%) or healthy controls (12%) [7]. As suggested by some MRI abnormalities, these abnormalities can either precedes the onset of psychosis as suggested by the neurodevelopmental models of schizophrenia or may develop progressively through the illness course [8].

The current study is a cross-sectional retrospective study aimed to estimate the prevalence of brain abnormalities visible on computed tomography (CT) scan or magnetic resonance imaging (MRI) in psychiatric patients admitted to Alain Hospital. The latter is the main tertiary hospital with multiple specialized facilities including a psychiatric ward with a 32 psychiatric inpatient beds located in the city of Alain, in the Gulf country of the United Arab Emirates. Alain hospital is the only psychiatric emergency receiving facility for that region with catchment area of around 750.000 population. It has an Electronic Health record system which was established in 2010. The electronic database of all patients admitted between January 2011 and December 2013 were reviewed and records of patients subjected to brain imaging were retrieved. Patients with previous radiological investigations were identified for inclusion into the study, and were given serial numbers for anonymity. Patients with multiple admissions were identified and were given only one serial number each regardless of the number of admissions. Figure 1 shows the sample selection procedure whereby a data collection form was designed for recording data of patients with both positive and negative radiological results. The form included the socio-demographic information, the clinical psychiatric presentation and the medical history of each patient.

2. Methods

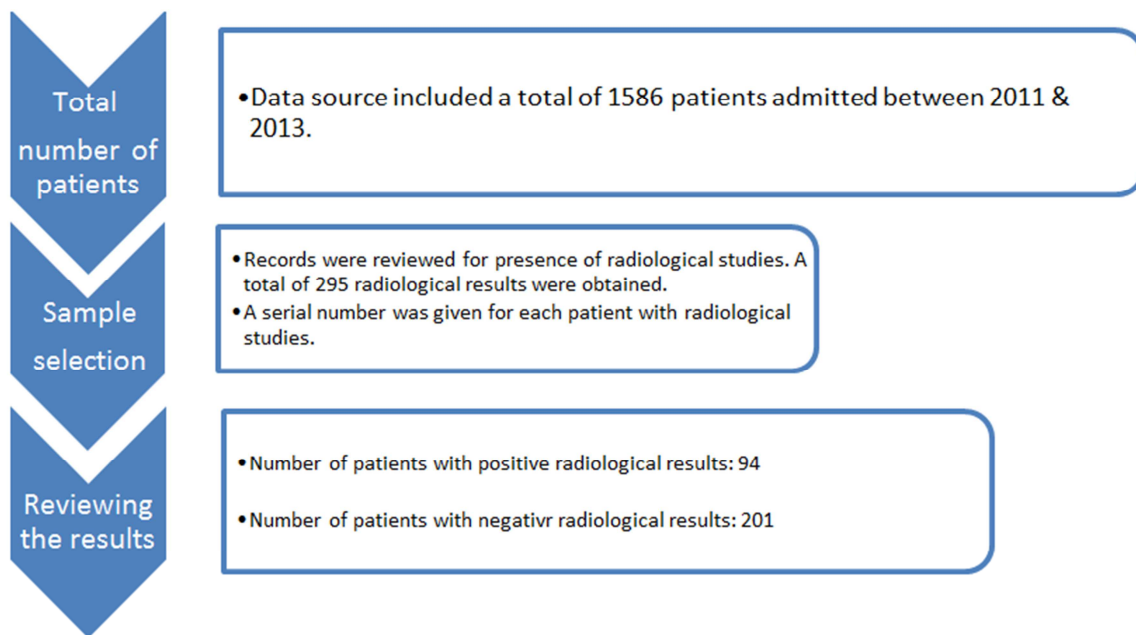


Figure 1. Selection procedure of the study sample.

We compared the group's positive and negative results accordingly. Data were analyzed using the SPSS version 21. We excluded from the analysis any uncompleted, uncertain or missing data. When we presented the results of our study, we indicated the number of sample with completed data in each of the tables and Chi-square was used to assess significance which was set at 0.05.

3. Results

3.1. Socio-demographic and Psychiatric Characteristics

A total 1586 patients were admitted to the psychiatric ward during the study period. Table 1 shows the Socio-

demographic and psychiatric characteristics of the of the entire study sample. Radiological investigations were ordered for 295 of these patients. Only 94 subjects had abnormal

findings which represent 32% of those patients subjected to radiological examination.

Table 1. Socio-demographic and clinical psychiatric characteristics.

Variable	Positive radiological findings	Negative Radiological findings	Statistical significance
Age groups (N=282)*			
Less than 20	03	18	
20 to 29	25	87	
30 to 39	28	48	P<0.0001
40 to 49	19	22	
50 to 59	07	11	
Over 60	12	02	
Total	94	188	
Gender (N=282)*			
Male	64	125	p= 0.449
Female	30	63	
Total	94	188	
Psychiatric diagnosis (N=265)*			
Mood disorder	39	12	
Schizophrenia	15	36	
Unspecified psychosis	10	17	P<0.0001
Dementia	3	0.0	
Personality disorder	5	7	
Others	14	89	
Total	94	171	
Number of psychiatric Episodes (N= 245)			
One	37	77	
Two	12	29	P=0.039
Three or more	43	47	
Total	92	153	
Duration since the first Episode (N= 208)*			
< One year	29	25	
1-2 years	6	27	
3-4 years	7	50	P< 0.0001
5 years or more	47	17	
Total	89	119	

*indicates number of cases valid for analysis.

As shown in table 1, we compared the positive and negative radiologic finding groups in regards to age and gender which revealed positive statistical significance for age (P<0.0001) but not for gender. There were statistically significant differences between the two groups when compared for the type of psychiatric diagnosis (p<0.0001), number of psychiatric episodes (p=0.039) and duration of psychiatric illness (P<0.0001).

Based on the documented clinical diagnosis; mood disorders were more common in patients with positive radiological findings, as they were reported in 39 patients (41.1%) compared with only 12 patients (4.5%) of those with negative radiological findings. On the other hand, Schizophrenia was the most common diagnosis among inpatients with negative results, and was reported in 36 patients (13.5%). Interestingly, the patients with positive radiological findings had more tendency to have a chronic psychiatric symptoms lasting for 5 or more years (52.8%), compared with 14.2% with similar duration among those

who had negative findings.

3.2. Types of Reported Radiologic Abnormalities

Table 2 shows the different types of reported radiological abnormalities. Cerebral calcifications was the most reported type and was found in 21 subjects representing 22.3% of the group with positive findings and 7.1% of overall patients. The most common site of calcification was reported in the basal ganglia. The later was studied separately compared with controls and the results of the study were previously published [9]. Calcification were also reported in falx cerebri, pineal gland and calcified frontal lobe meningioma. Other types of reported brain aberrations included evolutionary changes (dilated ventricles, atrophy and prominent sulci) existing in 13 patients which represent 4.4% of the total sample and 13.8% of those with positive findings. Similar number was reported for patients with findings of vascular lesions (ischemic changes / infarction).

Table 2. Types of lesions.

Type	Number of cases	% Positive group (N= 94)	% Total of positive and negative radiological findings (N=295)
Calcification	21	22.3	7.1

Type	Number of cases	% Positive group (N= 94)	% Total of positive and negative radiological findings (N=295)
Atrophy/ dilated ventricles/ prominent sulci	13	13.8	4.4
Vascular/ Infarction/ ischemic	10	10.6	3.4
Nonspecific hypo- or hyperdense lesions	13	13.8	4.4
Lesions involving the skull or sinuses	13	13.8	4.4
Gliosis/ surgery/ craniotomy	05	05.3	1.7
Multiple lesions	05	05.3	1.7
Others	14	14.9	4.7

3.3. Sites of Reported Lesions

Table 3 displays the reported Sites of lesions. The Basal ganglia was the most reported site of involvement occurring in 19 subjects and representing 6.4% of the total sample and 20.2% of those with positive findings. Lesions of basal

ganglia other than calcifications was reported in only 4 patients. We found that multiple sites involvement was also common, occurring in 16 patients which represent 17% of the group with positive sample and 5.4% of the total sample.

Table 3. Sites of lesions.

Site	Number of cases	% Subjects with Positive Radiologic findings (N=94)	% Total Subjects with radiological studies (N=94)
Basal ganglia	19	20.21	6.44
Multiple involvement	16	17.02	5.42
Skull and sinuses	16	17.02	5.42
Others	12	12.76	4.07
Frontal lobe	8	08.51	2.71
Temporal lobe	4	04.25	1.36
Ventricular/periventricular	4	04.25	1.36
Cisterns	4	04.25	1.36
Parietal lobe	3	03.19	1.02
Occipital lobe	2	02.13	0.68
Cortex	2	02.13	0.68
Meninges	2	02.13	0.68
Cerebellum	2	02.13	0.68

Frontal lobe lesions occurred in 8.5% of those with positive findings and 2.7% of the total sample. Temporal lobe, ventricular and periventricular areas, and cisterns had similar percentage each representing 4.2% of the positive group and 1.2% of the total sample. Occipital lobe, cerebellum, cortex and meninges were less common and each has been reported in 2.1% of the positive group and 0.6% of the total sample.

3.4. Medical History

Chronic medical conditions were reported in 50 out of 94 patients with positive radiological findings (53.2%)

compared with 35 out of 154 control subjects (22.7%) which has high statistical significance ($P < 0.0001$). The majority of patients with positive findings suffered from multiple medical conditions (25.5%) followed by neurological (8.5%), cardiac diseases (7.5%) and endocrine disorder (6.4%).

Reporting physical symptoms upon admission to the psychiatric ward was also common among those who had positive findings (46.8%) compared with only 3.7% of the control group ($P < 0.0001$).

Positive history of seizure was statistically significant finding that was reported in 25.5% of cases with positive findings and 15.6% of the control subjects ($P = 0.039$).

Table 4. Medical History in patients with positive findings compared with controls.

	Cases with positive findings N (%)	(Control) Cases with positive findings N (%)	Significance
Chronic medical conditions (N=248)*			
Endocrine	06 (6.4)	08 (5.2)	
Neurological	08 (8.5)	12 (7.8)	
Cardiac	07 (7.5)	03 (1.9)	$P < 0.0001$
Other	05 (5.3)	11 (7.1)	
Multiple medical conditions	24 (25.5)	0.0 (0.0)	
No history of chronic medical conditions	44 (46.8)	119 (77.3)	
Total	94 (100)	154 (100)	
Presence of physical symptoms on admission: (N= 257)*			
Present	44 (46.8)	06 (3.7)	$P < 0.0001$
Not present	50 (53.2)	157 (96.3)	
Total	94 (100)	163 (100)	

	Cases with positive findings N (%)	(Control) Cases with positive findings N (%)	Significance
History of seizure (N=261)*			
Positive history of seizures	24 (25.5)	26 (15.6)	P=0.037
Negative history of seizures	70 (74.5)	141 (84.4)	
Total	94 (100)	167 (100)	

* indicates number of cases valid for analysis.

4. Discussion

Structural brain imaging (CT scans and MRI) may be requested by psychiatrists in order to identify possible underlying organic etiology particularly for young patients and those who present at first-episode psychosis. Possible findings as suggested in the literature include brain injury, demyelination, brain tumors, multiple sclerosis or stroke [10]. Radiological investigations are frequently ordered for psychiatric patients. In one study, CT-head scans were ordered for 44.4% of patients with bipolar disorder, 23% of patients with dissociative disorder, and 21.6% of those with depressive disorder [11]. However, the radiologists may have different opinions and criticism regarding the radiological investigations for psychiatric patients and what to look for in such group of patients. In the past, the radiologists were concerned with reviewing findings to exclude any structural abnormality that might explain the psychiatric presenting symptoms such as temporal lobe abnormalities. Most of the time, radiological images were interpreted as normal, and were not helpful in work-up of psychiatric symptoms [12].

Therefore, retrospective study of the results obtained from the radiological examinations that were ordered based on clinical impression is essential as these data are accumulating over time and assumed to be ordered because of specific cause that made the presence of organic background more likely for the clinician who initially assessed the psychiatric symptoms. In some cases, routine radiological examination can lead to identification of rare or multi-system involvement [13]. If the psychiatric symptoms can be explained pathologically by an underlying disease process, the diagnosis is most likely to be a psychiatric disorder due to a medical condition, rather than primary/functional psychiatric illness. So, it is important to differentiate psychiatric symptoms directly related to organic causes from those coincidentally occurring in a patient suffering from a primary psychiatric disorder [14].

Our findings suggest that nearly one third of the results of radiological examinations have shown some sort of abnormal finding. These findings may not necessarily have direct explanation of presenting symptoms in a way that it can change the diagnosis or modify treatment plan. For example, presence of dilated ventricles or calcified brain lesions is not a direct explanation suggesting another diagnosis or alternative treatment plan for patients presenting with psychiatric symptoms such as schizophrenia or mood disorder. However, presenting the findings of radiological examinations can lead to further research aiming to give possible pathological explanation in the future, particularly when such findings are

associated with risk factors such as age, psychiatric presentation, duration of symptoms, number of episodes and presence of associated medical conditions that were all found to be statistically significant in our study. Follow-up radiological studies may be necessary in some cases as the radiological abnormalities may be progressive over time. In a recent review of patients with recurrent episodes of psychiatric illness, the brain abnormalities were not static but progressive showing extended changes with bilateral gray matter loss in different brain areas including the prefrontal cortex, hippocampus, amygdala, and basal ganglia [12].

The most common type of brain lesions in our study is calcification that was mostly present in basal ganglia. Other sites of calcifications include falx cerebri, pineal gland and calcified frontal lobe meningioma. Calcifications can suggest several differential diagnoses based on other clinical findings. Possible causes include tumors, vascular abnormalities, endocrine causes, infections and genetic factors [15]. The later finding together with presence of high medical comorbidity reported study population makes the possibility of systemic etiology more likely. This may also indicate that the radiological abnormality may appear not specific per se but if correlated with other risk factors can lead to identifying other diagnoses. Structural abnormalities on CT scans in people with schizophrenia include enlargement of the ventricles, cerebral sulci and fissure; and MRI studies confirm significant differences in ventricular volume and medial temporal structures [4].

5. Conclusion

Radiological abnormalities are common among psychiatric inpatients. Calcification and atrophic changes are the most common types of abnormality; and the most common sites of abnormality are the basal ganglia followed by abnormalities involving multiple sites. Future studies are needed to identify the potential significance of these findings and correlate them with patient's psychopathology.

Acknowledgements

All authors have declared no conflict of interest in relation to this research.

This study was conducted without any external funding.

References

- [1] Abiodun OA. Role of radiology in psychiatry: a review. *East Afr Med J.* 2005; 82 (5): 260-6.

- [2] Bunevicius A, Deltuva VP, Deltuviene D, Tamasauskas A, Bunevicius R. Brain lesions manifesting as psychiatric disorders: eight cases. *CNS Spectrum*. 2008; 13: 950–958.
- [3] Masdeu JC. Neuroimaging in psychiatric disorders. *Neurotherapeutics*. 2011; 8 (1): 93-102. doi: 10.1007/s13311-010-0006-0. PMID: 21274689; PMCID: PMC3052989.
- [4] Goulet K, Deschamps B, Evoy F, Trudel J-F. Use of brain imaging (computed tomography and magnetic resonance imaging) in first-episode psychosis: review and retrospective study. *Canadian Journal of Psychiatry*. 2009; 54: 493–501.
- [5] Lubman DI, Velakoulis D, McGorry PD, Smith DJ, Brewer W, Stuart G, Desmond P, Tress B, Pantelis C. Incidental radiological findings on brain magnetic resonance imaging were also reported in first-episode psychosis and chronic schizophrenia. *Acta Psychiatrica Scandinavica*. 2002; 106: 331–336.
- [6] McGuire P. Brain imaging and transition to psychosis. *Encephale*. 2010; 36 Suppl 3: S66–S70.
- [7] S J Borgwardt, E-W Radue, K Götz, J Aston, M Drewe, U Gschwandtner, S Haller, M Pflüger, R-D Stieglitz, P K McGuire, and A Riecher-Rössler. Radiological findings in individuals at high risk of psychosis. *J Neurol Neurosurg Psychiatry*. 2006; 77 (2): 229–233.
- [8] Pantelis C, Velakoulis D, McGorry P D. *et al* Neuroanatomical abnormalities before and after onset of psychosis: a cross-sectional and longitudinal MRI comparison. *Lancet* 2003361281–288.
- [9] Mufaddel A A, Osman OT, Al-Hassani G, Al-Bedwawi S, Hashim MJ. *Basal Ganglia Calcification in Psychiatric Inpatients: A Case-Control Study*. *Cogn Behav Neurol*. 2016 Sep; 29 (3): 139-43.
- [10] Ricardo Coentre, Amilcar Silva-dos-Santos, Miguel Cotrim Talina. Retrospective study on structural neuroimaging in first-episode psychosis. *PeerJ*. 2016; 4: e2069.
- [11] Gupta DK, Suthar N, Singh V, et al. Frequency and pattern of radiological and laboratory investigations in patients with mental illnesses: A study from North Rajasthan. *Indian J Psychiatry* 2016; 58 (2): 183-9.
- [12] Agarwal N, John D, Bazzocchi M, Renshaw PF. Update on the Use of MR for Assessment and Diagnosis of Psychiatric Diseases. *Radiology* 2010; 255: 1 (23-40).
- [13] Mufaddel A, AlSabousi M, Saleh B, Alhassani G, Osman OT. A Case of Gorlin-Goltz Syndrome Presented with Psychiatric Features. *Behavioural Neurology*. 2014; 10.3233/BEN-130355.
- [14] Mufaddel A, Omer AA, Salem MO. Psychiatric Aspects of Infectious Diseases. *OJP* 2014, 4, 202-217. doi: 10.4236/ojpsych.2014.43027.
- [15] Mufaddel A, Alhassani G. Familial Idiopathic basal ganglia calcification (Fahr's disease), *Neurosciences*, 2014: 19 (3), 171.